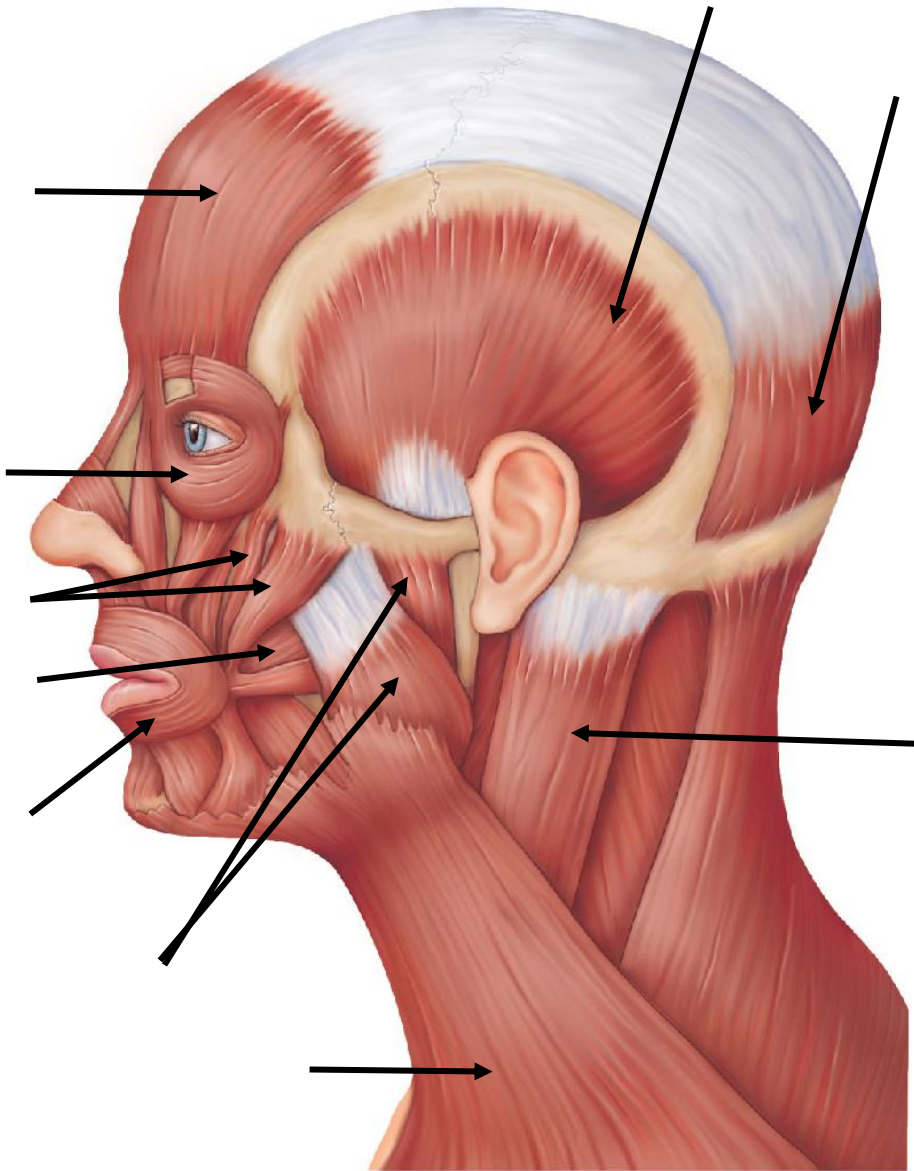


**Anatomy & Physiology**  
**Labeling Gross Anatomy of Skeletal Muscles**

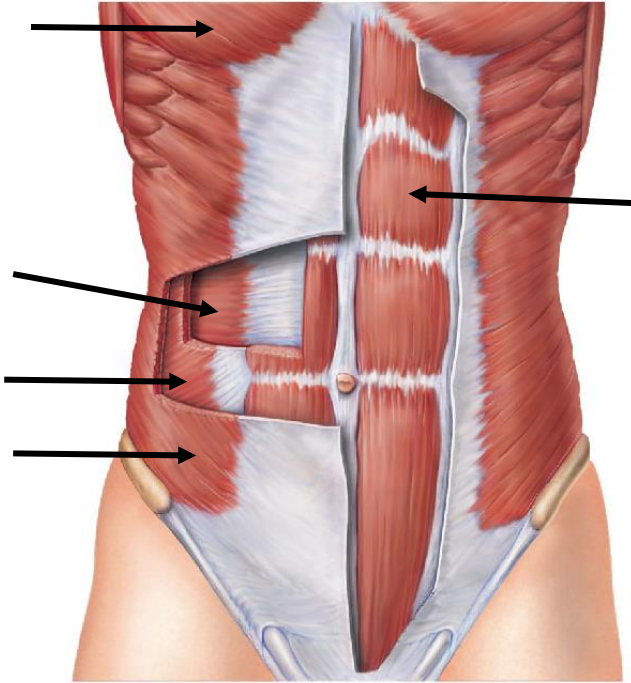
**Instructions:** Match the following muscles to their correct location.

**Head and Neck Muscles**

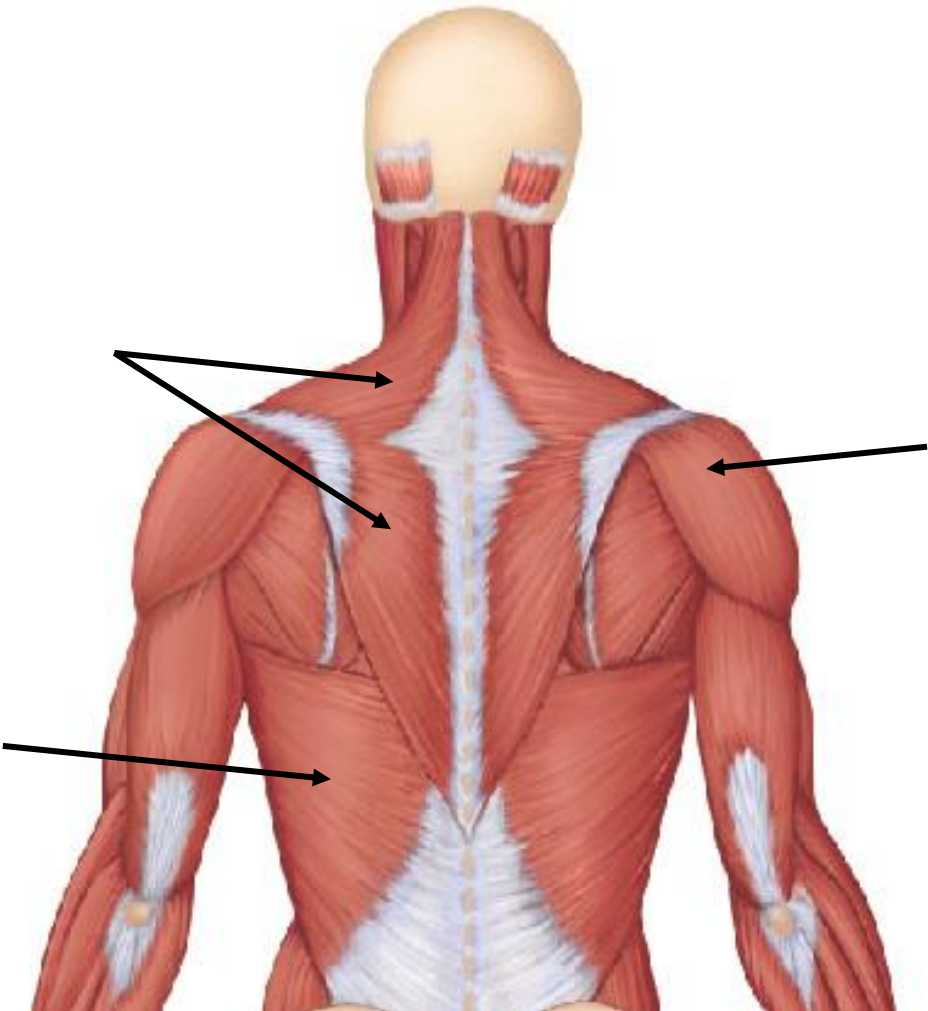


- a. frontalis
- b. orbicularis oculi
- c. orbicularis oris
- d. occipitalis
- e. buccinator
- f. zygomaticus
- g. masseter
- h. temporalis
- i. platysma
- j. sternocleidomastoid

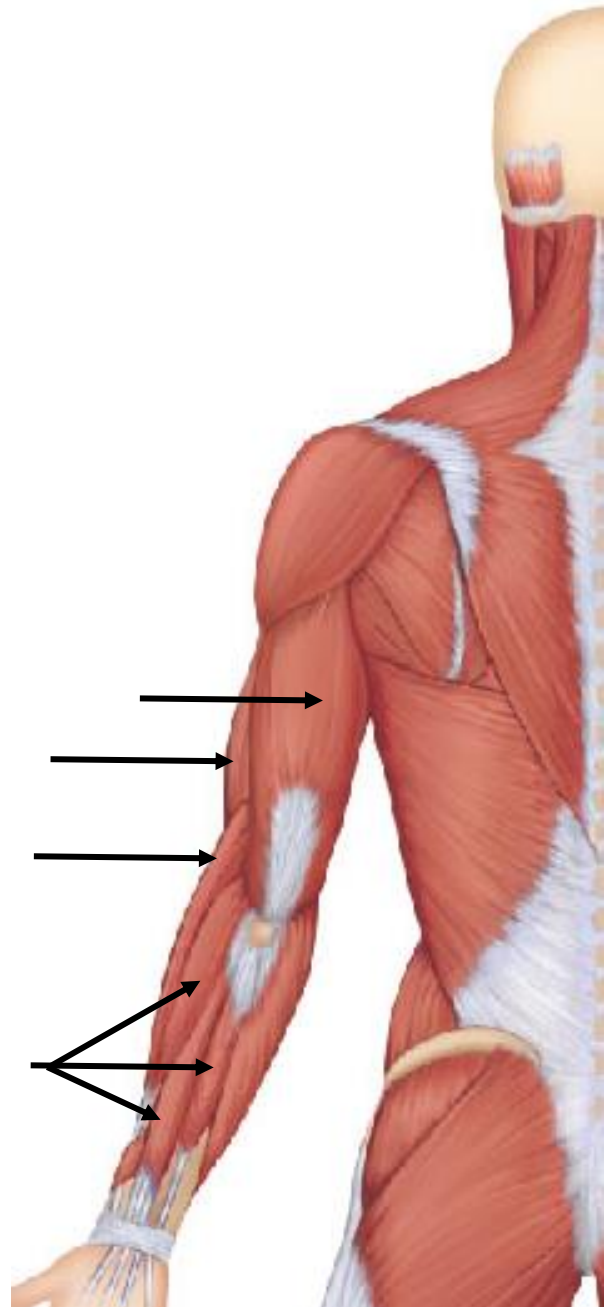
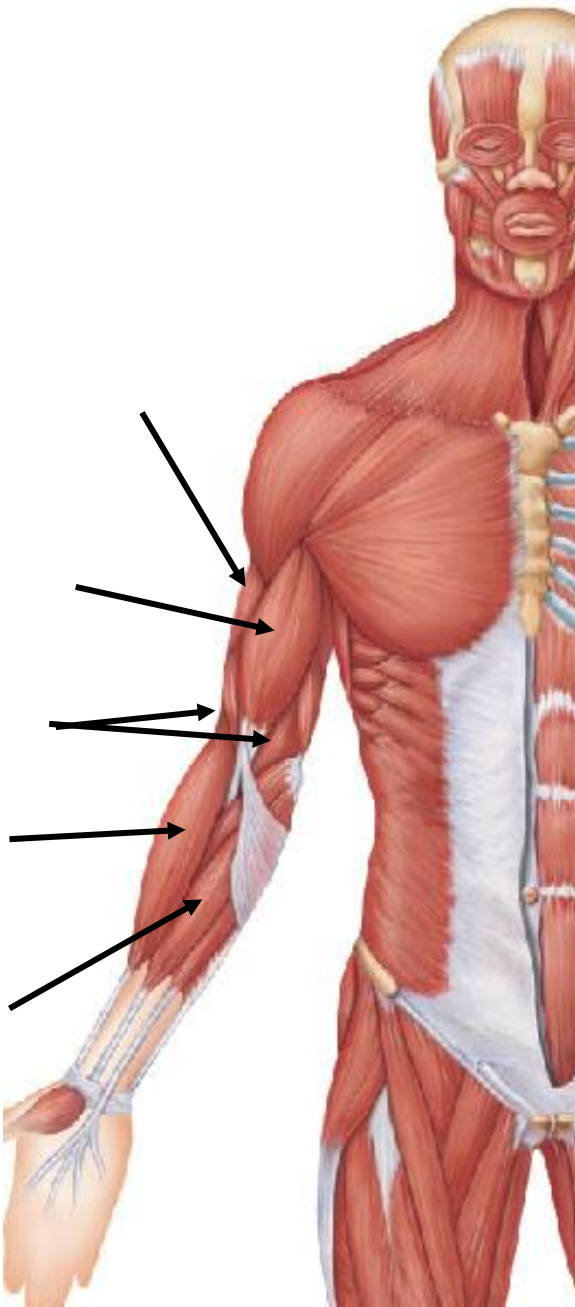
**Trunk Muscles**



- a. Pectoralis major
- c. Rectus abdominis
- d. External oblique
- e. Internal oblique
- f. Transverse abdominis
- g. Trapezius
- h. Latissimus Dorsi
- k. Deltoid

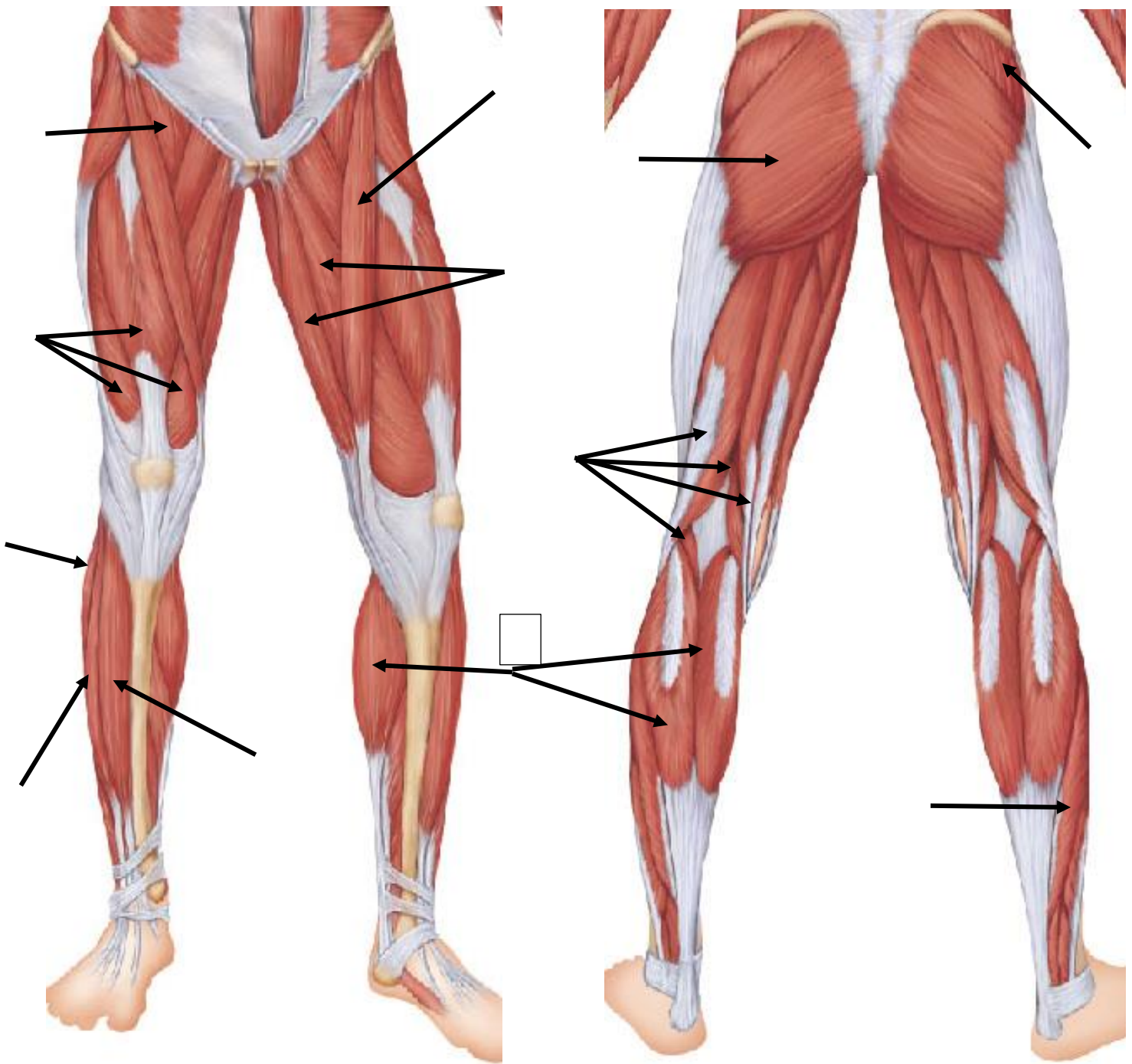


**Muscles of the Upper Limb**



- a. Biceps brachii
- b. Brachialis (anterior & posterior view)
- c. Brachioradialis (anterior & posterior view)
- d. Triceps brachii (anterior & posterior view)
- e. Flexor carpi radialis
- f. Extensor carpi & extensor digitorum

**Muscles of the Lower Limb**



- |                                     |                      |                              |
|-------------------------------------|----------------------|------------------------------|
| a. Gluteus maximus                  | b. Gluteus medius    | c. Iliopsoas                 |
| d. Adductor muscles (anterior view) | e. Hamstring group   | f. Sartorius                 |
| g. Quadriceps group                 | h. Tibialis anterior | i. Extensor digitorum longus |
| j. Fibularis muscles (anterior)     | k. Gastrocnemius     | l. Soleus                    |